

Case report

<https://doi.org/10.6065/apem.2019.24.4.253>
Ann Pediatr Endocrinol Metab 2019;24:253-256



First identified Korean family with Tatton-Brown-Rahman Syndrome caused by the novel *DNMT3A* variant c.118G>C p.(Glu40Gln)

Cha Gon Lee, MD, PhD¹,
Ja-Hyun Jang, MD, PhD²,
Ji-Young Seo, MD¹

¹Department of Pediatrics, Nowon Eulji Medical Center, Eulji University, Seoul, Korea

²GC Genome, Yongin, Korea

Tatton-Brown-Rahman Syndrome (TBRS), an overgrowth syndrome caused by heterozygous mutation of *DNMT3A*, first was described in 2014. Approximately 60 *DNMT3A* variants, including 32 missense variants, have been reported, with most missense mutations located on the *DNMT3A* functional domains. Autosomal dominant inheritance by germ-line mutation of *DNMT3A* has been reported, but vertical transmission within a family is extremely rare. Herein, we report the first Korean family with maternally inherited TBRS due to the novel heterozygous *DNMT3A* variant c.118G>C p.(Glu40Gln), located outside the main functional domain and identified by multigene panel sequencing. The patient and her mother had typical clinical features, including tall stature during childhood, macrocephaly, intellectual disability, and characteristic facial appearance. TBRS shows milder dysmorphic features than other overgrowth syndromes, potentially leading to underdiagnosis and underestimated prevalence; thus, targeted multigene panel sequencing including *DNMT3A* will be a useful tool in cases of overgrowth and unexplained mild intellectual disability for early diagnosis and genetic counseling.

Keywords: *DNMT3A*, Germ-line mutation, Tatton-Brown-Rahman syndrome, Growth disorder, Intellectual disability, High-throughput nucleotide sequencing, DNA sequence analysis

Introduction

Tatton-Brown-Rahman syndrome (TBRS, OMIM 615879) was recently identified as a novel overgrowth syndrome and was first described in 2014 by Tatton-Brown et al.¹⁾ TBRS is caused by heterozygous mutation of *DNMT3A* (OMIM 602769) on chromosome 2p23, which encodes a DNA methyltransferase.¹⁾ TBRS presents with faster than normal growth after birth, subtle abnormalities in facial features, and intellectual disability.¹⁾ Its prevalence is unknown. To date, over 60 *DNMT3A* variants, including 32 missense variants, have been reported in the medical literature.¹⁻⁹⁾ Notably, vertical transmission within a family by germ-line mutation is extremely rare in reports of TBRS.⁶⁾ *DNMT3A* is an epigenetic modifier and consists of 3 major protein domains: the Pro-Trp-Trp-Pro domain, the ATRX-DNMT3-DNMT3L domain, and the catalytic methyltransferase domain.¹⁰⁾ Most reported missense variants associated with TBRS are located in one of these 3 functional domains, suggesting their potential deleterious impact on protein function.^{1-5,9)}

This report describes, for the first time in Korea, a mother and daughter carrying the novel heterozygous *DNMT3A* variant c.118G>C p.(Glu40Gln), which was located outside the 3 main functional domains and was identified by multigene panel sequencing. The mother and daughter showed typical clinical features of TBRS.

Received: 21 December, 2018

Revised: 28 January, 2019

Accepted: 11 February, 2019

Address for correspondence:

Ji-Young Seo, MD

Department of Pediatrics, Nowon Eulji Medical Center, Eulji University, 68 Hangeulbiseok-ro, Nowon-gu, Seoul 01830, Korea

Tel: +82-970-8226

Fax: +82-970-0068

E-mail: pedseo@eulji.ac.kr

<https://orcid.org/0000-0003-3471-7803>

This is an Open Access article distributed under the terms of the Creative Commons Attribution Non-Commercial License (<http://creativecommons.org/licenses/by-nc/4.0>) which permits unrestricted non-commercial use, distribution, and reproduction in any medium, provided the original work is properly cited.

ISSN: 2287-1012(Print)

ISSN: 2287-1292(Online)

Case report

The proband is an 11-year-old girl with intellectual disability who visited our clinic. She was born vaginally at full term, weighing 3,800 g (10–25th percentile), to nonconsanguineous parents. The pedigree of the family is illustrated in Fig. 1A. Her motor development was within the normal range, but she exhibited apparent expressive language delays and did not use words with meaning until approximately 3–4 years old. She had experienced recurrent seizures and received treatment with an antiepileptic drug for approximately 2 years at ages 4–6 years. She had been treated by a child psychologist for intermittent explosive disorder and early childhood depression. In a physical examination at 11 years of age, she showed overgrowth, with a height of 163.7 cm (+2.27 standard deviation [SD]), weight of 67 kg (+2.43 SD), body mass index of 25 kg/m² (+1.94 SD), and head circumference of 57 cm (+3.82 SD). She had a round face, horizontal eyebrows, depressed nasal bridge, and anteverted nares, as shown in Fig. 1B. She had no joint hypermobility, hypotonia, or kyphoscoliosis. Neurodevelopmental evaluation showed mild intellectual disability with a Full Scale IQ of 67 according to the Korean Wechsler Intelligence Scale for Children, fourth edition. Laboratory tests, including complete blood count with blood cell morphology, chemistry, electrolytes, and pituitary function, were within normal ranges. Brain magnetic resonance imaging was normal.

The patient's mother was 40 years old when she visited the clinic with her daughter. She was the fifth child of healthy nonconsanguineous parents. She had no family history of neurological disease, developmental delay, intellectual disability, or overgrowth during childhood other than her daughter. She had a history of faster than normal growth after infancy. She was taller than her peers and elder sisters during childhood, but her growth stopped after adolescence. She presented with global developmental delay from infancy. Her exact intelligence quotient was not measured, but she had apparent intellectual disability with a learning disability. Her highest education was junior high school. She exhibited macrocephaly, with a head circumference of 57 cm (+3.82 SD) and obesity with a height of 164.4 cm (75th percentile, +0.67 SD), weight of 93.3 kg (+3.54 SD), and body mass index of 35.4 kg/m² (+4.04 SD). She had a round face, as shown in Fig. 1C, with an appearance different from that of her sisters. She had no other known past medical history. Laboratory tests, including complete blood count with blood cell morphology, were within normal ranges.

For differential molecular diagnosis of overgrowth and intellectual disability syndrome, we performed multigene panel sequencing with a TruSight One Sequencing Panel (Illumina, San Diego, CA, USA), which sequenced the genes *AKT3*, *BRWD3*, *CHD8*, *CDKN1C*, *DNMT3A*, *DIS3L2*, *EZH2*, *GPC3*, *GPC4*, *NFIX*, *NSD1*, *PIK3CA*, and *PTEN*. Genomic DNA was extracted from the patient's peripheral blood leukocytes

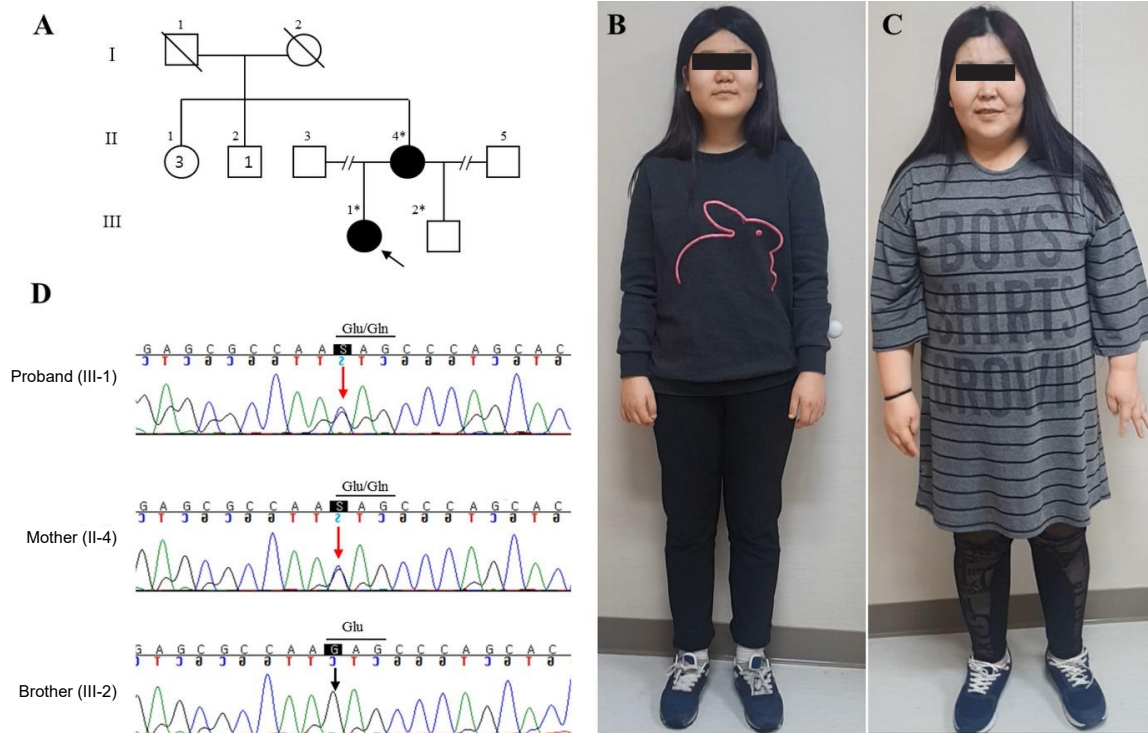


Fig. 1. (A) Pedigree of the family. Asterisks indicate sampled subjects. (B) Photograph of the proband (III-1). At 11 years of age, she exhibits a round face, horizontal eyebrows, depressed nasal bridge, and anteverted nares. (C) Photograph of the patient's mother (II-4). At 40 years of age, she exhibits a round face. (D) Sanger sequencing confirmed the *DNMT3A* variant c.118G>C p.(Glu40Gln) in the patients (II-4 and III-1) and the wild-type genotype in an unaffected family member (III-2).

and sequenced on the Illumina MiSeq platform at Green Cross Genome (Yongin, Korea). Alignment of sequence reads, indexing of the reference genome (hg19), and variant calling with a pipeline based on GATK Best Practice was performed at Green Cross Genome. The coverage and depth data of the candidate genes are summarized in Supplemental Table 1. The heterozygous missense variant c.118G>C p.(Glu40Gln) of *DNMT3A* was identified on the basis of the reference sequence NM_022552.4 and was classified as a variant of uncertain significance (VUS) along with PM2 (absent from populations such as gnomAD, ExAC, 1000g, and KRDB) and PP3 (multiple lines of computational evidence, including SIFT, PolyPhen-2, MutationTaster, support a deleterious effect) according to the guidelines of the American College of Medical Genetics and Genomics.¹¹ This variant was confirmed by Sanger sequencing of samples from the affected family members (the proband and her mother) and from the proband's unaffected brother. Her mother also harbored the heterozygous missense variant. Sanger sequencing results are presented in Fig. 1D.

Discussion

Overgrowth syndromes are a clinically heterogeneous group of diseases defined by height and/or head circumference more than 2 SD above the mean, together with additional phenotypic abnormalities, the most common of which is intellectual disability.¹² Various overgrowth conditions are believed to be associated with elevated risks of cancer. *DNMT3A* somatic mutations are well known to be associated with hematological malignancies, especially acute myeloid leukemia, and *DNMT3A* germ-line mutations are associated with TBRS.¹⁰ TBRS was recently recognized as a single-gene disorder associated with overgrowth and intellectual disability. Tatton-Brown et al. reported that *DNMT3A* accounted for 2.5% of the single-gene mutations causing overgrowth and intellectual disability in individuals.¹²

Only a few patients have been reported with missense variants located outside the main functional domains.⁹ Interestingly, the p.(Glu40Gln) variant identified in the present study was located in the N-terminal region outside the 3 main functional domains, mapped to a UniProt Knowledgebase sequence. This novel variant is absent from controls such as the Korean Reference Genome project, which involved whole genome sequencing of 622 and 1,100 Korean individuals. Although from a small, single family, the patients in this family case showed typical clinical features of TBRS, and the variant was cosegregated with disease in the family. The variant site is predicted to be highly conserved in nucleotide conservation prediction analysis (GERP++, PhastCons, PhyloP, and SiPhy). Thus, the novel missense variant is suggested to be a disease-causing variant and responsible for the phenotype observed in the family. Our findings expand the genotype spectrum of patients with *DNMT3A*-related TBRS and are expected to further contribute to interpretation of

VUSs.

The phenotype in our cases is characterized by faster than normal growth of height and head size during childhood, normal growth after late adolescence, and obesity after adulthood. Additionally, the phenotype includes subtle dysmorphic facial features and mild intellectual disability. That these dysmorphic features are relatively mild compared to those observed in other overgrowth and intellectual disability syndromes, such as Sotos syndrome (OMIM 117550), Weaver syndrome (OMIM 277590), and Malan syndrome (OMIM 614753), may have led to underdiagnosis and underestimated prevalence of TBRS, diagnosis of which can only be confirmed through genetic testing. Thus, targeted multigene panel sequencing including *DNMT3A* may prove a valuable diagnostic tool in patients with overgrowth and unexplained mild intellectual disability for early diagnosis and family genetic counseling.

In summary, we described for the first time a Korean family with the novel heterozygous *DNMT3A* variant c.118G>C p.(Glu40Gln), which was located outside the 3 main functional domains and was identified by multigene panel sequencing.

Conflict of interest

No potential conflict of interest relevant to this article was reported.

Acknowledgments

This research was supported by the Basic Science Research Program through the National Research Foundation of Korea (NRF), funded by the Ministry of Science, ICT, & Future Planning (2014R1A1A1A1007569).

Ethical statement

The Institutional Review Board of Nowon Eulji Medical Center (EMCS 2018-11-035) approved the use of human clinical materials and blood in this study. Written informed consent for publication of medical photographs and genetic test results was obtained from the patient and her parents.

Supplementary material

Supplementary Table 1 can be found via <http://doi.org/10.6065/apem.2019.24.4.253>.

References

1. Tatton-Brown K, Seal S, Ruark E, Harmer J, Ramsay E, Del Vecchio Duarte S, et al. Mutations in the DNA methyltransferase gene *DNMT3A* cause an overgrowth syndrome with intellectual disability. *Nat Genet* 2014;46:385-8.

2. Xin B, Cruz Marino T, Szekely J, Leblanc J, Cechner K, Sency V, et al. Novel DNMT3A germline mutations are associated with inherited Tatton-Brown-Rahman syndrome. *Clin Genet* 2017;91:623-8.
3. Tlemsani C, Luscan A, Leulliot N, Bieth E, Afejar A, Baujat G, et al. SETD2 and DNMT3A screen in the Sotos-like syndrome French cohort. *J Med Genet* 2016;53:743-51.
4. Evers C, Staufner C, Granzow M, Paramasivam N, Hinderhofer K, Kaufmann L, et al. Impact of clinical exomes in neurodevelopmental and neurometabolic disorders. *Mol Genet Metab* 2017;121:297-307.
5. Kosaki R, Terashima H, Kubota M, Kosaki K. Acute myeloid leukemia-associated DNMT3A p.Arg882His mutation in a patient with Tatton-Brown-Rahman overgrowth syndrome as a constitutional mutation. *Am J Med Genet A* 2017; 173:250-3.
6. Lemire G, Gauthier J, Soucy JF, Delrue MA. A case of familial transmission of the newly described DNMT3A-Overgrowth Syndrome. *Am J Med Genet A* 2017;173:1887-90.
7. Okamoto N, Toribe Y, Shimojima K, Yamamoto T. Tatton-Brown-Rahman syndrome due to 2p23 microdeletion. *Am J Med Genet A* 2016;170A:1339-42.
8. Shen W, Heeley JM, Carlston CM, Acuna-Hidalgo R, Nillesen WM, Dent KM, et al. The spectrum of DNMT3A variants in Tatton-Brown-Rahman syndrome overlaps with that in hematologic malignancies. *Am J Med Genet A* 2017;173:3022-8.
9. Tatton-Brown K, Zachariou A, Loveday C, Renwick A, Mahamdallie S, Aksglaede L, et al. The Tatton-Brown-Rahman Syndrome: a clinical study of 55 individuals with de novo constitutive DNMT3A variants. *Wellcome Open Res* 2018;3:46.
10. Yang L, Rau R, Goodell MA. DNMT3A in haematological malignancies. *Nat Rev Cancer* 2015;15:152-65.
11. Richards S, Aziz N, Bale S, Bick D, Das S, Gastier-Foster J, et al. Standards and guidelines for the interpretation of sequence variants: a joint consensus recommendation of the American College of Medical Genetics and Genomics and the Association for Molecular Pathology. *Genet Med* 2015;17:405-24.
12. Tatton-Brown K, Loveday C, Yost S, Clarke M, Ramsay E, Zachariou A, et al. Mutations in epigenetic regulation genes are a major cause of overgrowth with intellectual disability. *Am J Hum Genet* 2017;100:725-36.